



PRESENTING CLINICAL SIGNS

DATE History: Murmur. Cushings disease – receiving trilostane. Gall bladder sludge.

4/18/22

ECHOCARDIOGRAPHIC FINDINGS
2D, M-mode, and Doppler study.

PERFORMED BY: Left atrial size is normal. The mitral valve leaflets are mildly thickened, and a mild jet of eccentric mitral regurgitation is present. Left ventricular dimensions are normal. Left ventricular systolic function is hyperdynamic. The aorta and aortic valve are normal. Right atrial and right ventricular dimensions are normal. The tricuspid valve is normal. The pulmonary artery and pulmonic valve are normal. No pericardial effusion or cardiac masses are seen.

Dana Alterman,
RDCS, LVT

INTERPRETED BY

Keith Blass, DVM,
MS, DACVIM
(Cardiology)

LA – 19.9 mm
LVIDd – 19.1 mm
LVIDs – 10.4 mm
FS – 45.5%
RA – 37.4 mm
LVOT – 1.24 m/s
RVOT – 0.84 m/s

PATIENT

Coco Puff Telles

ELECTROCARDIOGRAPHIC FINDINGS
A single lead ECG is submitted for review.

SPECIES

HR: 162 bpm
Rhythm: Sinus

Canine

Mild sinus tachycardia is present throughout this recording. All complex amplitudes and intervals are within normal limits. No premature beats or conduction blocks are seen.

BREED

Chihuahua Mix

ASSESSMENT/RECOMMENDATIONS
Degenerative mitral valve disease

This examination demonstrates mild regurgitation of blood across Coco Puff’s mitral valve resulting from degenerative valve disease. The hemodynamic effects of the regurgitation also appear to be mild, as Coco Puff does not have secondary dilation of either of her left heart chambers, and her left ventricular systolic function is well-preserved. As such, Coco Puff’s mitral valve disease appears to be well-compensated, and her current risk for the development of clinical signs secondary to it, such as coughing, exercise intolerance, syncope, and labored breathing, appears to be low.

SEX

FS

AGE

No abnormalities are appreciated in Coco Puff’s ECG.

12 y

No therapy is recommended at this stage of disease.

WEIGHT

A recheck echocardiogram is recommended in 6 months to monitor for disease progression.

11.26 lb

HOSPITAL NAME

Eubank AC

REFERRING VET

Dr. Russman



DATE

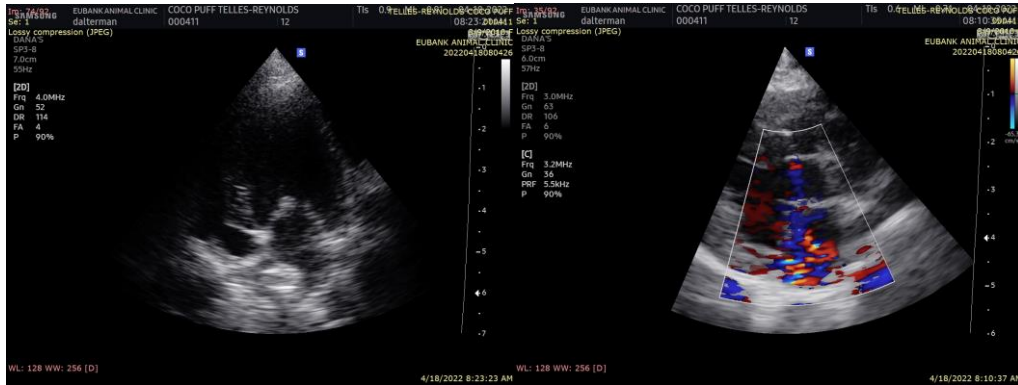
4/18/22

PERFORMED BY:

Dana Alterman,
RDMS, LVT

INTERPRETED BY

Keith Blass, DVM,
MS, DACVIM
(Cardiology)



The information and recommendations provided are based on the images presented by the referring veterinarian. No evaluation can be communicated regarding pathology that was not visible in the image/video clips provided.

Thank you for this referral. If the clinical or image interpretation does not parallel your findings or if I can be of any further assistance please contact me.

PATIENT

Coco Puff Telles

Keith Blass, DVM, MS, DACVIM (Cardiology)
KeithBlass@gmail.com
631-804-5754

SPECIES

Canine

BREED

Chihuahua Mix

SEX

FS

AGE

12 y

WEIGHT

11.26 lb

HOSPITAL NAME

Eubank AC

REFERRING VET

Dr. Russman